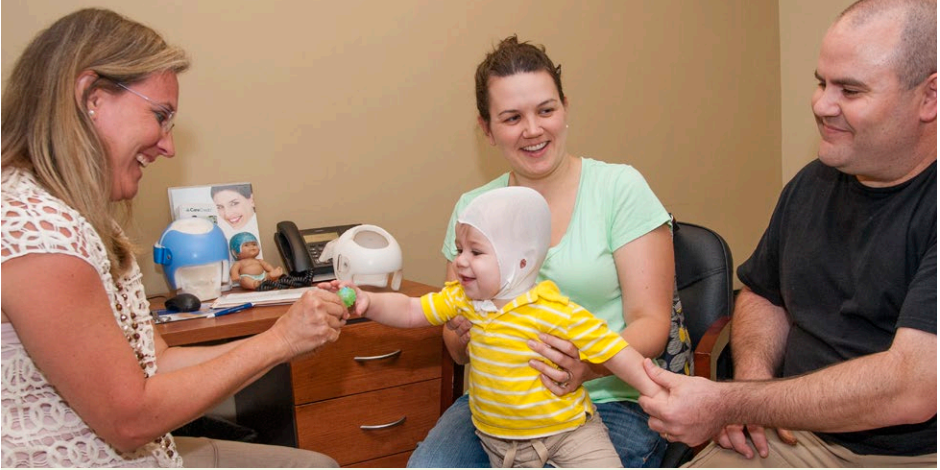

Clinical Guide

Orthotic Management of
Pediatric Cranial Deformities
using STAR Cranial
Remolding Orthoses



By Dulcey Lima, CO, OTR/L



Introduction

The number of skull deformities reported in babies has increased since 1992, coinciding with the timing of the international effort by physicians to recommend a supine sleeping position

worldwide. At about the same time this program was initiated, cultural practices for the way we carry and position our babies also changed with the advent of new daytime “holding” devices. This combination of supine sleeping, parental fear of SIDS connected with prone positioning and excessive use of daytime carriers created the “perfect storm” for the development of deformational head shape deformities. Reports from craniofacial teams across the world confirm that the number of babies referred for these conditions has risen sharply.^{2, 3, 4, 5}

Causes Of Headshape Deformities

A skull deformity in a young baby is defined herein as an asymmetry in the shape, cranial vault or height of the baby’s skull or a disproportional relationship of the width to the length of the skull with accompanying abnormal features. The skull can assume an abnormal shape due to intrinsic factors like prematurely



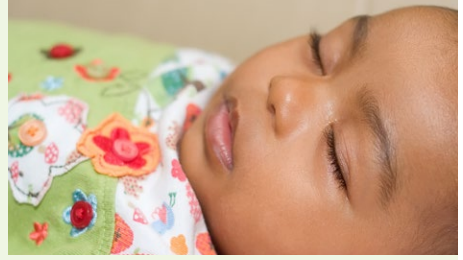for babies as a strategy for reducing Sudden Infant Death Syndrome (SIDS). This very successful “Back to Sleep” Program has reduced SIDS by 40%¹ and is supported by health care providers

closed sutures (Craniosynostosis) and/or genetic or metabolic anomalies including Osteogenesis Imperfecta or abnormal development of the skull plates and sutures. Babies who develop hydrocephalus secondary to cerebral dysfunction or other causes are also at risk to develop skull deformities, possibly due to the need to maintain a supine position for monitoring, and the abnormal amount of cerebral spinal fluid impacting the soft cranial bones.⁶ Babies with congenital anomalies of the cervical spine can also develop Plagiocephaly secondary to the faulty bony alignment of the vertebrae. Head shape deformities as a result of intrinsic factors are not on the increase and are not the subject of this publication; however these conditions can also pre-dispose the baby to extrinsic abnormal molding of the skull due to medical issues, procedures, or delays that causes the baby's head to rest in one position.

Extrinsic factors that contribute to skull deformities are well documented and can begin in the uterus. Congenital causes include Torticollis, breech positioning, multiple fetuses, oligohydramnios, and a difficult or prolonged delivery of the baby.^{7, 8, 9, 10} Most skull deformities resolve in about 6 weeks after birth once the deforming force is removed. But if the baby has Torticollis or neck muscle asymmetry that is not identified, or if the baby is not positioned in a variety of ways to unload the areas of flattening, the skull deformity may not resolve and can actually worsen over time.⁹

Post-natal extrinsic factors can also affect the newborn skull as seen in premature babies whose skulls are less calcified than

those of full term babies, and also babies who require prolonged hospitalization until they are medically stable. Term and preterm infants may develop abnormal head shapes "due to medical treatment, nursing care practices, positioning



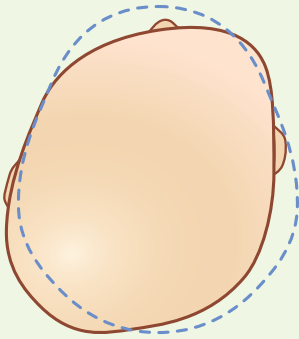
limitations and underlying muscle tone abnormalities".¹¹ The literature has long verified that sleep position affects the proportion of the width to length ratio of the infant's skull (Cephalic Ratio). Babies who sleep supine develop a wider face and shorter skull than infants who sleep prone or mix their sleeping positions.¹² This type of head shape is not abnormal unless it is accompanied by vertex height and frontal deformities. Researchers have found that parenting practices such as bottle feeding on one side and tummy time <3x day contributed to Deformational Plagiocephaly at 7 weeks.¹³

Impact Of Neck Asymmetry On The Cranium

Researchers consistently report that Torticollis is strongly associated with asymmetrical deformities of the infant skull. It is unclear if the Torticollis predisposes babies to Deformational Plagiocephaly or whether the Plagiocephaly predisposes the babies to developing Torticollis.¹⁴ The neck

asymmetry, whether caused by weakness or limitation in range, impacts the baby's ability to rotate and tip the head in a variety of positions. Over time, the prolonged contact against a hard surface deforms the skull and limits normal developmental skills like rolling. Hutchison prospectively studied 200 children born at a single institution and identified criteria for determining whether a baby had Plagiocephaly or Brachycephaly. She found a significant link between Torticollis and neck preference with those babies whose deformity did not resolve by 2 years of age.¹⁵

Deformational Plagiocephaly



The most common head shape deformity in young infants is deformational Plagiocephaly. This is an asymmetrical deformity of the cranium caused by extrinsic factors. In its most severe presentation, there is impressive posterior and anterior asymmetry of the skull accompanied by ear, orbit, cheek, and jaw asymmetry. No person is perfectly symmetrical, so it is important to differentiate severity levels in order to provide appropriate intervention. Studies by Clarren¹⁶, Moss¹⁷, Mulliken¹⁸,

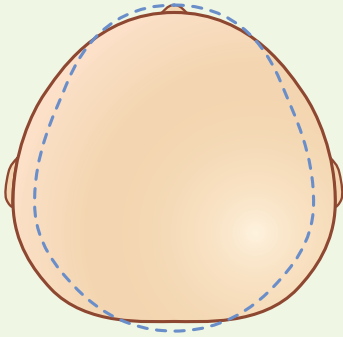
de Chalain¹⁹, Vles²⁰, Graham⁹, and others have attempted to separate the infants with mild deformities from those who require orthotic management. All studies recommend that infants with mild deformities without other compounding features be monitored, repositioned, and provided with frequent prone activities during the day. These studies recommend that infants with moderate-to-severe deformities be treated with custom cranial remolding orthoses if efforts at therapy and/or repositioning fail to correct the deformity.



Graham considered "normal" symmetry as $< .3\text{cm}$ in diagonal difference (DD) in the vertex. He recommended treating infants with repositioning if the DD was $> 1\text{ cm}$ and the baby is < 4 months old. For babies between 4 and 6 months, Graham gave parents a choice between repositioning and orthotic management. Babies who failed to respond to the repositioning and therapy and failed to reduce their DD to less than 1cm by 7.4 months were referred for orthotic management.⁹ An alternative to taking caliper measurements of the cranium is to optically divide the infant's head into 4 quadrants with the head in midline, and assess how many of the quadrants are abnormal. Infants with 2 or more

quadrants involved, especially those with frontal asymmetry or ear shift should be referred early to prevent sensory problems or developmental delays.

Deformational Brachycephaly

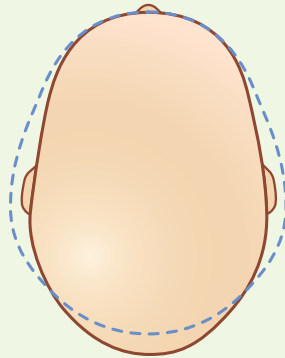


Symmetrical Brachycephaly is characterized by skull that is abnormally wide for its length. In its most severe presentation, the central occipital flattening is accompanied by peaking of the vertex of the head, abnormal widening of the parietal bones, severe sloping of the vertex and pronounced frontal bossing. Argenta Study reports that the widening of the parietal bones and vertical skull growth is “an attempt at further decompression of the brain by vertical growth or temporal bulging.”²⁷ Graham points out that Brachycephaly may be associated with syndromes

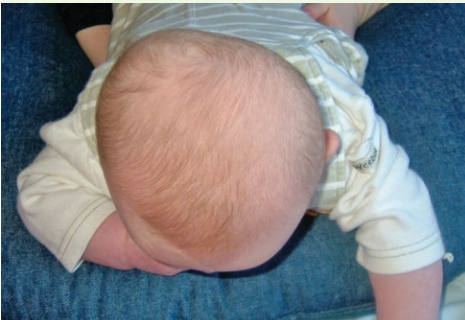that affect the “pliability of the infant’s skull or an infant’s tendency to remain recumbent.”²² In moderate-to-severe Symmetrical Brachycephaly, the wide parietal bossing may act as a barrier to rolling and full rotation to each side while the baby is supine. Babies with Symmetrical Brachycephaly also have poor neck extensor strength which limits the acquisition of head and neck control.

Asymmetrical Brachycephaly is a head shape deformity characterized by asymmetry and disproportion. The vertex is often high and asymmetrical. Frontal asymmetry and ear shift may also be present.

Deformational Scaphocephaly



Babies with Deformational Scaphocephaly have a head shape that is long and disproportionately narrow. It is the least common deformational head shape deformity, and is usually associated with premature infants who are positioned in side-lying in the NICU. Recent attention to repositioning these babies has reduced the incidence of this deformity. When it occurs, the narrow occiput makes midline positioning of the head difficult, and the baby’s head tends to fall over to one side



or the other. This impacts the ability to develop neck extension against gravity and midline head and neck control.

Differentiating Deformational Head Shape Deformities From Craniosynostosis

The American Academy of Pediatrics (AAP) recommends that the pediatrician assess the infant for Torticollis, assess the infant's head at every visit, advise parents about repositioning strategies, and refer the infant for therapy if the neck tightness, weakness, or developmental delays do not resolve. It is also important for physicians to understand the differences in the head shape of infants with Deformational Plagiocephaly and Craniosynostosis to ensure the



appropriate treatment.¹⁴ Infants with deformational changes benefit from repositioning and orthotic management. Infants with Craniosynostosis require surgical intervention to facilitate normal brain and skull growth.²³ The differentiation between the two conditions is usually made clinically; however an MRI and/or CT scan may be ordered if there is concern about Craniosynostosis. Excellent articles have been published that provide diagrams and written explanations of the clinical



differentiation process. In general, infants with Craniosynostosis tend to have ridging over the affected suture(s), an ear that is close to an area of flattening rather than shifted away as in Plagiocephaly, and no bossing ipsilateral to the quadrant of flattening. When Craniosynostosis is suspected, the infant is generally referred to a specialist for a complete craniofacial evaluation and possible surgical intervention.^{24, 25}

Repositioning and Therapeutic Intervention

Previous sections of this paper have discussed the importance of placing babies on their backs to sleep and providing time for prone positioning while the baby is awake and supervised. Prone activities foster the acquisition of motor milestones in addition to relieving pressure on the flattened occiput. Prone positioning also promotes neck extension and head turning—and provide opportunities to stretch and lengthen the muscles of the neck and shoulder girdle.

Caregivers need to understand the impact of their own child care practices on their child's developmental skills, and the symmetry and proportion of the baby's skull. However, even with perfect parenting and positioning, head shape deformities may not resolve—especially if Torticollis is present. An excellent

caregiver educational booklet was developed by the staff at Children's Healthcare of Atlanta and Orthomerica Products to provide activities to help prevent head shape deformities. This booklet discusses the importance of prone positioning to promote the development of head and trunk control and the acquisition of gross and fine motor skills. "Tummy Time Tools", currently available in English, Spanish, Japanese and French, can be downloaded free of charge at **starbandkids.com** or **choa.org**.²⁶ If repositioning and stretching exercises are unsuccessful in an infant with significant deformity, the child may be referred for a cranial remolding orthosis. Referral should be considered as early as three months of age if the deformity is severe or is interfering with rolling or visual tracking.



STAR Cranial Remolding Orthoses

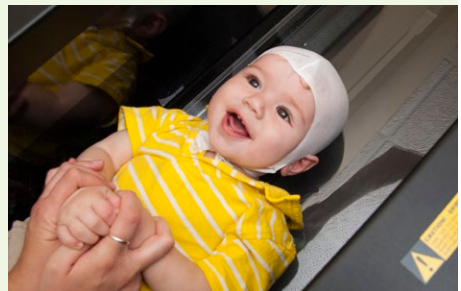STAR Cranial Remolding Orthoses derive their name from their purpose — *Symmetry Through Active Remolding*.



These custom orthoses are fabricated from an exact model of the infant's cranium to obtain optimum fit and

function. The rigid outer shell maintains the structural design integrity and is either lined with closed cell foam to allow progressive adjustments or is made of a clear thermo-plastic material which allows easy visual inspection of the areas of contact and voids within the orthosis. Each of the unique STAR Cranial Remolding Designs can be modified throughout the treatment program to accommodate growth, promote symmetry, and improve proportion. Usually, only one band is required for the entire treatment program.

All STAR Cranial Remolding Orthoses with STARscanner™ Laser Data Acquisition System have FDA 510(k) clearance, a requirement of all U.S. companies who manufacture orthoses intended to remold the cranium. The STARscanner is one of the safest Class 1 laser scanning



systems currently available with FDA clearance to scan infants with head shape deformities. Other laser scanners used to fabricate orthotic and prosthetic devices are new Class 1 and Class 2 scanners and depend on a person's corneal reflex (blink reaction) to look away or close the eyes to prevent eye damage from the laser. Since babies have an immature blink reflex and blink infrequently compared to adults who blink every 2-10 seconds²⁷,

Class 2 scanners may place the eyes of young babies at particular risk during the scanning process if the blink reflex is not yet mature.

STAR Cranial Remolding Orthosis Treatment

The STAR Treatment Program focuses on redirecting cranial growth toward greater symmetry and proportion. This is accomplished by maintaining contact over the areas of bossing and allowing room for growth inside the orthosis in the areas where the infant's skull is depressed or flattened.

The practitioner makes progressive adjustments through multiple appointments over the course of the treatment program to accommodate and direct skull growth into a more symmetrical and well-proportioned shape.

Unlike prefabricated helmets that come in only two sizes, custom STAR Cranial Remolding Orthoses are uniquely designed for each infant to hold key areas of the skull and limit abnormal/asymmetrical vertex height and diagonals, and normalize the shape of the parietal and frontal bones.

The initial visit includes a thorough patient evaluation, gathering of patient history, and discussion with the infant's primary caregiver(s). Consultation with the prescribing physician and physical or occupational therapist ensures a cohesive orthotic treatment program. Once the treatment has been explained, the orthotist makes an exact

duplicate of the infant's head from a plaster impression or scan from the STARscanner. The plaster impression method of duplicating the infant's head shape provides a mold which is used to fabricate a cranial remolding orthosis and the casting process takes 15-20 minutes. The orthotist lays a series of plaster splints over the infant's head to capture the cranial shape. The negative mold is cured and shipped to Orthomerica for fabrication of a STAR Cranial Remolding Orthosis. The infant is fit with the orthosis within two weeks of the cast or scan

date. The practitioner provides the

caregiver(s) with daily care instructions, describes the wearing schedule, and provides contact information in the event an adjustment is needed before the next scheduled appointment. Frequent follow-up visits are

scheduled to monitor the infant's rapid cranial growth and ensure that the skull is growing into the proper quadrants to achieve a greater degree of symmetry and proportion. On average, treatment programs with a STAR Cranial Remolding Orthoses range from three to six months with most infants completing treatment in about 4½ months with 9-10 patient visits. Infants older than twelve months may require a longer treatment program due to the normal decrease in skull growth after this time and the increased thickness and rigidity of the cranium. Research indicates that the greatest symmetry can be attained through early intervention,⁷ but some correction is still possible in infants up to 18 months of age.²⁸



STARscanner Laser Data Acquisition System

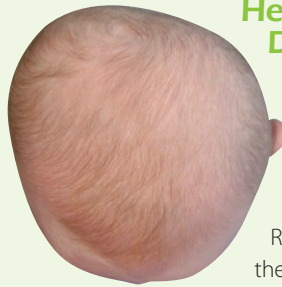Some facilities providing STAR cranial treatment use the STARscanner Laser Data Acquisition System to acquire the shape of the infant's head rather than casting the infant's head. This Class 1 scanning device is a safe and accurate means of collecting infant head shape data and takes less than 1.5 seconds. The STARscanner eliminates the casting process, and uses a combination of eye safe lasers and cameras to capture surface data of the infant's head shape. This electronic encrypted file is sent to Orthomerica via email. Using CAD/CAM technology, a 5-axis Carver creates a 3-D model of the infant's head for fabrication.

Efficacy of the STARband Cranial Remolding Orthoses

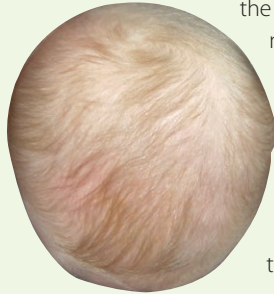A study published in the Journal of Craniofacial Surgery from researchers at Children's Healthcare of Atlanta studied the effectiveness of the STARband using the STARscanner for shape acquisition and documentation. This study also documented 16 infants diagnosed with Deformational Plagiocephaly whose families declined treatment. All but three of the untreated subjects only changed in parameters related to growth and did not improve significantly in symmetry or proportional variables. The 206 infants

treated with the STARband demonstrated significant improvement in all 25 variables including those related to cross sectional measurements and volume comparisons between right and left anterior, posterior and overall symmetry ratios.²⁹

Can STAR Cranial Remolding Orthoses Help Resolve The Deleterious Effects Of Head Shape Deformities?



Before STARband Treatment



After STARband Treatment

The more rounded occipital portion of STAR Cranial Remolding Orthoses allows the infant's head to turn more freely instead of resting on the flattened area of the occiput. The bossed area no longer acts as a barrier to rolling, allowing the infant to turn easily—facilitating the development of more advanced motor skills. The orthosis also provides space in the affected flattened areas to prevent further deformity at night when the baby is supine and when the infant is positioned for protection

in the car seat. In both of these positions, the infant has more neck mobility in the STAR Orthosis because the more rounded occipital area allows symmetrical turning and midline positioning. Many caregivers report that their babies begin to roll and are more active after they begin orthotic treatment. No study has ever documented that cranial remolding orthoses interfere with skill development although there is certainly clinical

evidence that prior to any intervention, babies with Deformational Plagiocephaly may have developmental issues^{30, 31, 32}, visual tracking problems³³, mandibular asymmetry³⁴, and auditory issues.³⁵

Since 2000, over 100,000 infants have benefited from the STAR Cranial Remolding Orthosis Program. The child's physical appearance is transformed by the treatment process as the head is gently re-shaped to improve symmetry and proportion. Perhaps even more importantly, STAR Cranial Remolding Orthoses help normalize the position of the skull plates and frontal bones to ensure that the child's rapidly expanding brain can process sensory information from a more normal mid-line orientation. This treatment program provides non-invasive intervention that positively impacts a child's development for a lifetime.

REFERENCES

1. Experts link infant sleep position to SIDS risk; AAP advises placing babies on sides, backs. *AAP News*. 1992; 8:5:1
2. Kane AA, Mitchell LE, Craven KP, Marsh JL. Observations on a Recent Increase in Plagiocephaly Without Synostosis. *Pediatrics*. June 1996; 97(6): 877-885.
3. Turk AE, McCarthy JG, Thorne CH, Wisoff JH. The "Back to Sleep Campaign" and Deformational Plagiocephaly: Is There Cause for Concern? *J Craniofac Surg*; 1996; 7(1):12-18
4. Chaddock WM. The enigma of lambdoid molding. *Pediatr Neurosurg* 1997; 26:304-311
5. Argenta LC, David LR, Wilson JA, et al. An increase in infant cranial deformity with supine sleeping position. *J Craniofac Surg*. 1996; 7:5-11.
6. Kumar R. Positional Molding in Premature Hydrocephalics. *Neurol India*. 2002; 50: 148-152
7. Kelly KM, Littlefield TR, Pomatto JK. Importance of Early Recognition and Identification of Deformational Plagiocephaly with Orthotic Cranioplasty. *Cleft Palate Craniofac J* 1999; 36:127-130
8. Teichgraeber JF, Ault JK, Baumgartner J, Waller A, Messersmith M. Deformational Posterior Plagiocephaly: Diagnosis and Treatment. *Cleft Palate-Craniofac J*. 2002; 39:582-586
9. Graham JM, Gomez M, Halberg A, Earl DL, Kreutzman JT, Cui J, Guo X. Management of Deformational Plagiocephaly: Repositioning Versus Orthotic Therapy. *J Pediatr* 2005; 146:258-262
10. Hutchison BL, Thompson JM, Mitchell E. The Determinants of Nonsynostotic Plagiocephaly: A Case Controlled Study. *Pediatrics*. 2003; 112(4)
11. Hummell P, Fortado D. Impacting Infant Head Shapes. *Advances in Neonatal Care* 2005; 5(6):329-340
12. Huang CS, Cheng HC, Lin WY, Liou JW, Chen YR. Cleft palate Craniofac J. Skull Morphology Affected by Different Sleep Positions in Infancy. 1995; 32(5):413-419
13. Van Vlimmeren LA, van der Graaf Y, Boere-Boonekamp M, L'Hoir MP, Helden PJ, Engelbert RH. Risk Factors for Deformational Plagiocephaly at Birth and at 7 Weeks of Age: A Prospective Cohort Study. *Pediatrics*. 2007; 119:e408-e418



14. Peitsch WK, Keefer CH, LaBrie RA, et al.
Incidence of cranial asymmetry in healthy newborns *Pediatrics*. 2002;110:1-8
15. Hutchison BL, Hutchison AD, Thompson JM, Mitchell EA
Plagiocephaly and Brachycephaly in the First Two Years of Life: A Prospective Cohort Study *Pediatrics*. 2004;114: 970-980
16. Clarren SK
Plagiocephaly and torticollis: etiology, natural history, and helmet treatment. *J Pediatr* 1981;98:92-95
17. Moss SD
Nonsurgical, nonorthotic treatment of occipital plagiocephaly: what is the natural history of the misshapen head? *J Neurosurg*. 1997;87: 667-670
18. Mulliken JB, VanderWoude DL, Hansen M, et al.
Analysis of posterior plagiocephaly: deformational versus synostotic *Plast Reconstr surg* 1999;103: 371-380
19. Loveday BP, de Chailin TB
Active counterpositioning or orthotic device to treat positional plagiocephaly? *J Craniofac Surg* 2001;12:308-313
20. Vles JS, Colla C, Weber JW, et al.
Helmet versus nonhelmet treatment in non synostotic positional plagiocephaly *J Craniofac Surg* 2000;11:572-574
21. Argenta L.
Clinical Classification of Positional Plagiocephaly *J Craniofac Surg*. 2004;15(3):368-372
22. Graham JM, Kreutzman J, Earl D, Halberg a, Samayoa C, Guo X
Deformational Brachycephaly in Supine-Sleeping Infants *J Pediatr* 2005; 146:253-7
23. Persing J, James H, Swanson J, Kattwinkel J
Prevention and Management of Positional Skull Deformities in Infants *Pediatrics*;2003;112:1:199-202
24. Huang MHS, Gruss JS, Clarren SK, et al.
The differential diagnosis of posterior plagiocephaly: true lambdoid synostosis versus positional molding. *Plast Reconstr Surg*. 1996;98:756-774
25. Biggs W.
Diagnosis and management of positional head deformity *Am Fam Physician*. 2003; 67:1953-1956.
26. Coulter-O'Berry C, Lima D.
Tummy Time Tools.
Children's Healthcare of Atlanta and Orthomerica Products, Inc. 2007
27. Lawrensen JG, Birhah R, Murphy LJ
Tear-film liquid layer morphology and corneal sensation in the development of blinking in neonates and infants. *J Anat*. 2005; 206:3:265-270
28. Littlefield TR, Pomatto JK, Kelly KM
Dynamic orthotic cranioplasty: treatment of the older infant *Neurosurg Focus* 2000;53:367-377
29. Plank LH, Giavedoni B, Lombardo JR, Geil MD, Reisner A
Comparison of Infant Head Shape Changes in Deformational Plagiocephaly Following Treatment with a Cranial Remolding Orthosis Using a Noninvasive Laser Shape Digitizer *J Craniofac Surg*. 2006; 17:6:1084-1091
30. Panchal J, Amirshaybani H, Gurwitch R, Cook V, Francel P, Neas B, Levine N
Neurodevelopment in Children with Single-Suture Craniosynostosis and Plagiocephaly without Synostosis *Plast Reconstr Surg* 2001; 108:1492
31. Miller RI, Clarren SK
Long-term developmental outcomes in patients with deformational plagiocephaly *Pediatrics* 2000;105:e26
32. Kordestani RK, Patel S, Bard D, Gurwitch R, Panchal J
Neurodevelopmental Delays in Children with Deformational Plagiocephaly *Plast Reconstr Surg* 117: 207, 2006
33. Siatkowski MR, Fortney AC, Nazir SA, Cannon SL, Panchal J, Francel P, Feuer W, Ahmad W
Visual Field Defects in Deformational Posterior Plagiocephaly *J AAPOS*; 2005;9:274-278
34. Kane AA, Lo LJ, Vannier MW, Marsh JL
Mandibular Dysmorphology in Unicoronal Syostosis and Plagiocephaly without Synostosis *Cleft Palate-Craniofac Journal*. September 1996; 33(5):418-421
35. Balan P, Kushnerenko E, Sahlin P, Huotilainen M, Naatanen R, Hukki J
Auditory ERPs Reveal Brain Dysfunction in Infants with Plagiocephaly *J Craniofac Surg*; 2002; Jul;13:4:520-525





Like us on
Facebook



starband®

When nature needs a nudge™

www.STARbandkids.com

© 2013 Orthomerica Products, Inc. All Rights Reserved.
This represents proprietary material which cannot be reproduced
without the express written consent of Orthomerica.

SL00121 Rev. C | Cat. No. 726